

A 14-year Follow-up of Resin Composite Occlusal Restorations: Split Mouth Randomised Clinical Trial and Wear Evaluation by Optical Coherence Tomography

LUÍS FELIPE ESPÍNDOLA-CASTRO¹, RENATA PEDROSA GUIMARÃES², FÁBIO BARBOSA DE SOUZA³, GABRIELA QUEIROZ DE MELO MONTEIRO⁴, PAULO FONSECA MENEZES FILHO⁵, LUANA OSÓRIO FERNANDES⁶, CLAUDIO HELIOMAR VICENTE DA SILVA⁷

ABSTRACT

Introduction: The search for restorative materials with clinical longevity has led to modifications in the composition of the resin composites.

Aim: To evaluate the clinical performance and the occlusal wear of posterior restorations with one microhybrid (Suprafill/SS White) and two condensable/packable (Filtek P60/3MESPE and Surefil/Dentsply Caulk) resin composites.

Materials and Methods: Sixty restorations (n=20) were performed in 2002 in 20 patients. Class I and II cavities were restored with the studied resin composites in a split-mouth design. Evaluations were done at baseline, 1 and 14-years regarding colour stability, marginal discolouration and integrity, caries incidence, and anatomic form according to the USPHS criteria (United States Public Health Service). OCT (Optical Coherence Tomography) images of the gypsum replica were analysed to observe the wear of the restorations at the buccal and lingual cusps. Data was

evaluated through Friedman's test and Wilcoxon signed ranks post hoc test ($p=0.05$).

Results: Differences were not observed between the evaluated resin composites regarding each of the analysed parameters ($p>0.05$). However, for each resin composite, differences were observed between the observation periods through Friedman's test ($p<0.001$), except for caries incidence. Differences were observed when the 14-year data for colour match, anatomic form and marginal adaptation was compared. After 14 years, Surefil presented lower unsatisfactory evaluations when compared to the other groups (only two). No significant differences were found between the buccal and lingual cusps ($p>0.05$).

Conclusion: The condensable/packable resin composites and microhybrid presented similar performance after 14 years. The cast replica analysis by OCT was a viable method for follow-up evaluations consistent with the clinical observations.

Keywords: Clinical evaluation, Dental restoration failure, Longevity

INTRODUCTION

Resin composites are the standard first choice for a direct restorative procedure. The need for aesthetic and durable restorative materials is increasing, and modifications are continually emerging in the materials' composition and operative techniques [1,2]. The material's properties and usage according to correct indications are factors that may influence the long-term performance of the restorations [3,4]. Colour stability, marginal sealing, fracture resistance, and long-term wear are factors that should be considered when selecting a restorative material [5,6].

Microhybrid resin composites combine filler particles of different sizes (0.4 to 1 μm), up to 75-80% load in weight, and are 55-60% in volume, with good mechanical properties and surface smoothness [4,7,8]. They are indicated for anterior and posterior regions, including areas of increased masticatory activity [9]. In Class II preparations, condensable or packable resin composite restorative materials were developed to facilitate material insertion and the establishment of adequate proximal contact [8,10]. Their higher viscosity is related to the monomer composition or a higher filler content [10,11]. This increase (above 80% in volume) in the microhybrid resin composites, has been reported to lead to less polymerisation shrinkage and reduced wear rates [4,7].

Abrasive wear may be visualised due to the reduction in the organic matrix or due to filler particle detachment, especially in the marginal gaps [12]. However, direct clinical evaluations do not allow the quantification of structural loss, therefore requiring indirect analysis as complementary tests [13,14]. The use of OCT acts as a non-destructive

and simple alternative that enables micrometric evaluation of internal structures and surfaces [15]. OCT is based on the principle of low-coherence interferometry [16]. In dentistry, OCT has been reported to detect early mineral changes, aiding the diagnosis of early caries and dental erosion. The method can still be used in the evaluation of internal and marginal adaptation of sealants and resin composite restorations, and dental wear measurement [17-21].

The complexity of the oral cavity makes the resin composites susceptible to colour changes due to external pigment accumulation, dehydration, water sorption, chemical degradation and surface roughness [22,23]. Short-term clinical evaluations of resin composite restorations on posterior teeth have shown a satisfactory performance of these materials. However, further assessments are fundamental for validation of their use in these regions [24-26].

Thus, this clinical study aimed to evaluate the clinical performance of microhybrid and condensable resin composite posterior restorations regarding the colour stability, marginal discolouration and integrity, caries incidence, and anatomic form after 14 years. Additionally, the occlusal wear of the restorations was evaluated through replica observations using OCT analysis.

MATERIALS AND METHODS

Study Design

This controlled, randomised, double-blind (patient and examiner) clinical trial with three groups (Filtek P60, Surefil and Suprafill) and similar allocation rate (split-mouth design) was approved by the local ethics committee of Universidade Federal de Pernambuco/PE-

Brazil (protocol n. 43327415.3.0000.5208). The trial was registered at ReBEC (<http://www.ensaiosclinicos.gov.br>) under RBR-8gcd45 and followed the recommendations of the Consolidated Standards of Reporting Trials-CONSORT.

Population, Sample Size, and Eligibility Criteria

The study was held at the dental school of the Universidade Federal de Pernambuco (Recife, Pernambuco, Brazil). Patients older than 21 years (mean age 25.67±6.32) that attended the dental clinics were recruited for the study beginning in July 2002 [27]. The sample size was 20 occlusal restorations per group (60 in all). After 14 years, 7 patients were included in this study. Twenty-one restorations were evaluated between July and December 2016.

Inclusion criteria were as follows: 1) need for occlusal restorations in at least three posterior teeth with primary caries, or the need to replace a restoration; 2) good general health; 3) sound or adequately restored opposing teeth [27]. The exclusion criteria were as follows: 1) periodontal disease; 2) teeth with endodontic treatment; 3) teeth with painful symptomatology. After 14 years, patients who performed any modification in the teeth selected for the research (replacement of the restoration, extraction, total crowns or any other procedure that would impede the clinical evaluation) were also excluded.

Allocation Sequence, Randomisation and Blinding

A total of 60 restorations were done on 20 patients by the same operator. Each patient received 3 restorations, each one with one of the 3 evaluated restorative materials. The allocation sequence was determined following the quadrants (upper left, upper right, lower right and lower left). In the same quadrant, the restorations always began with the most distally located tooth. The split-mouth design assured that all patients received restorations from all three experimental groups [Table/Fig-1]. Brown sealed envelopes were

used to assure allocation concealment and randomness. Patients and evaluators were blinded to which restorative material was placed [Table/Fig-2].

	Maxillary Premolar	Mandibular Premolar	Maxillary Molar	Mandibular Molar	p-value*
FiltekTM P60/3M/ ESPE	1	1	1	4	0.925
Surefil/Dentsply Caulk	2	2	0	3	
Suprafill/SS White	1	1	2	3	
TOTAL	4	4	3	10	

[Table/Fig-2]: Distribution of the studied restorative materials within restored teeth.
*Through Fisher's-Exact Test.

Clinical Procedures

The restorative materials used are described in [Table/Fig-1]. Two packable (Filtek P60 and Surefil) and one microfill (Suprafill) resin composites were evaluated in this study. The microfill Suprafill served as a control group.

The restorative procedures were performed following the protocol: 1) cavity preparation using high-speed diamond burs and low-speed round burs; 2) rubber dam isolation; 3) prophylaxis with a brush and pumice stone (ultrafine/SS White, São Cristóvão, Brazil); 4) bonding agent application; and (5) restorative procedures according to manufacturer's instructions [Table/Fig-1]. In shallow and medium cavities, no pulp protection procedures were performed. In deep cavities (at least 0.5 mm of remaining dentin between the cavity floor and pulp chamber), glass ionomer cement was applied as a liner before the bonding agent. In very deep cavities (0.5 mm or less of remaining dentin), calcium hydroxide cement followed by glass ionomer cement was applied before the bonding agent. In very deep cavities with pulp exposure, Ca(OH)₂ solution was used, followed by the application of Ca(OH)₂ powder over the exposure, followed by the cement. Glass ionomer cement was then applied before the bonding agent. All photopolymerisation procedures were done using halogen light of 600 mW/cm² (Optilight Plus/Gnatus, Brazil) within the times recommended by the manufacturers.

Clinical Evaluation

Two examiners were previously calibrated (Kappa=0.88) using the USPHS (United States Public Health Service) criteria [Table/Fig-3]. Consensus answers were given for each parameter, where satisfactory restorations were scored as Alpha (ideal) or Bravo (clinically acceptable). Charlie and Delta scores were considered unsatisfactory therefore failure. The evaluation was performed with the aid of a dental mirror and explorer probe. For the colour match, the evaluation was done under natural light. The evaluation occurred at the baseline, 12 months and after 14 years.

The indirect evaluation was performed through replicas made of cast at baseline and after 14 years of placement. The impression of the restorations was obtained using condensation silicone (Precise SX Kit/Dentsply-Milford/USA) which was then poured with type IV gypsum (Troquel/Polidental-Cotia/Brazil). All cast models were analysed using spectral domain OCT at 930 nm central wavelength (SR-930, Callisto Imaging System, Thorlabs). The system has a 1.7 mm/1.3 mm imaging depth with 7.0 µm/5.3 µm axial resolution (air/water) and 8 µm lateral resolutions. The cast replicas were positioned over the translational stage of the scanner stand, in an individualised silicone device used for image standardisation [Table/Fig-4]. A 6-mm scanning range was done in the lingual-buccal direction in the 2-D mode. The mean values per group were calculated for further statistical analysis.

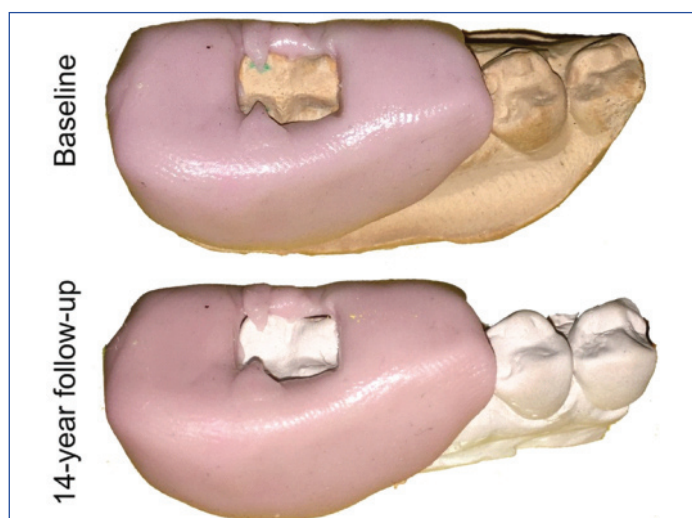
The restoration wear was measured by analysing the distance (µm) between the cavosurface angles (buccal and lingual) and the deepest point of the central pit which served as reference points. For each point, the difference between baseline measurements

Materials	Composition	Application	Manufacturer Batch n.
FiltekTM P60+Singlebond	Organic Matrix: Bis-GMA, UDMA with Bis-EMA Inorganic fillers: Particles of zirconia and silica (0.01-3.5 µm). 83% in volume and 45% in weight. Packable	Bond: Application of 2 consecutive layers of Single Bond, air jets for 5 seconds and photopolymerisation for 10 seconds Resin composite: 2 mm thick increments were applied and photoactivated for 20 seconds.	3M-ESPE, St. Paul, USA (9AT2002-10) (0BG2003-07)
Surefil+Prime & bond NT	Organic Matrix: UDMA. Inorganic fillers: Glass particles of Ba-B-F, SiO ₂ (0.1-0.8 µm). 77-82% in volume and 58-66% in weight. Packable	Bond: Apply a generous amount of Prime & Bond NT Adhesive, remain for 20 seconds, air jets for 5 seconds and photopolymerisation for 10 seconds Resin composite: 2 mm thick increments were applied and photoactivated for 40 seconds.	Dentsply Caulk, Milford, USA (990325) (990526)
Suprafill+Suprafill Bond	Organic Matrix: Bis-GMA, UDMA and TEDMA. Inorganic fillers: Particles of Silicate or Barium Glass (0.05-2 µm). 60% in volume and 76.5% in weight. Microhybrid	Bond: Application of 2 layers with 5 seconds air jets after each layer. Photopolymerisation for 20 seconds Resin composite: 2 mm thick increments were applied and photoactivated for 20 seconds.	SSWhite, São Cristóvão, Brazil (Uninformed)

[Table/Fig-1]: Composition, application, manufacturer and batch number of each material used.
Reference: author (based on information provided by manufacturers)

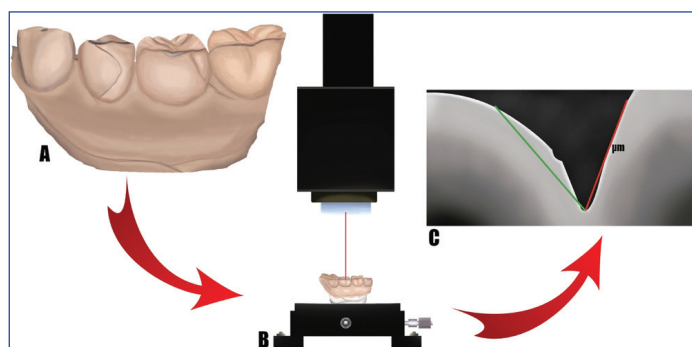
Parameters	Scores
Colour match	<i>Alpha (A)</i> -matches the colour and translucency of the tissues surrounding the restoration
	<i>Bravo (B)</i> -does not match the colour and translucency of the tissues surrounding the restoration, with acceptable mismatching.
	<i>Charlie (C)</i> -do not match the colour and translucency of the tissues surrounding the restoration, with unacceptable mismatching.
	<i>Delta (D)</i> -could not be scored without the aid of the dental mirror.
Cavosurface margin discolouration	<i>Alpha (A)</i> -no evidence of marginal discolouration.
	<i>Bravo (B)</i> -discolouration without axial penetration.
	<i>Charlie (C)</i> -discolouration with axial penetration.
Caries incidence	<i>Alpha (A)</i> -no caries lesion.
	<i>Charlie (C)</i> -the presence of caries lesion.
Anatomic Form	<i>Alpha (A)</i> -shows the anatomic shape continuity.
	<i>Bravo (B)</i> -evident superficial cavity.
	<i>Charlie (C)</i> -material loss with dentin exposure.
Marginal adaptation	<i>Alpha (A)</i> -closely adapted, no detectable margin with explorer.
	<i>Bravo (B)</i> -detectable margin, clinically acceptable without dentin exposure
	<i>Charlie (C)</i> -marginal cavity failure up to the enamel-dentin junction.

[Table/Fig-3]: Clinical evaluation through the USPHS method.



[Table/Fig-4]: Individualised silicone device for indirect cast replica analysis.

and after 14 years of clinical use, was calculated. The amount of lost material was not analysed as the restorations were three-dimensional structures, rather the increase in the distance between the reference points was measured. [Table/Fig-5] illustrates schematically how the images were obtained and how the distance measurements were taken.



[Table/Fig-5]: Schematic diagram of OCT analysis.

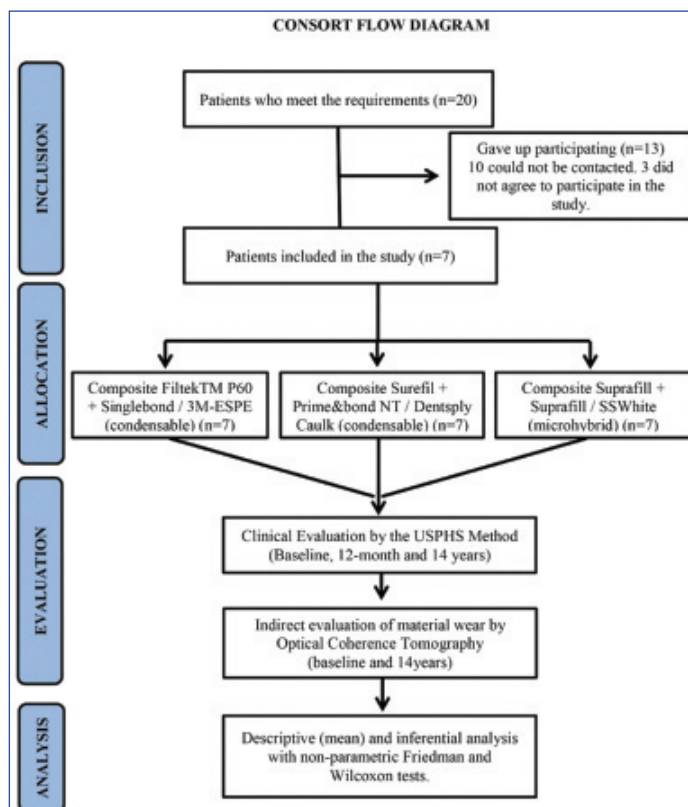
(a) Cast replica (Baseline and 14 anos); (b) positioning of the replicas in the central portion of the OCT and movement with micrometric buttons; (c) measurement between the cavosurface angles (buccal and lingual) and the deepest point of the central pit (line red and green).

STATISTICAL ANALYSIS

Data were inserted into Excel and analysed descriptively. Inferential analysis was performed with non-parametric Friedman's tests for the comparison between the resin composites. Wilcoxon test was applied for paired data in the comparison between wear assessments through OCT. The margin of error used in the decision of the statistical tests was 5% and the software used for the statistical analysis was the SPSS (Statistical Package for the Social Sciences), version 23.

RESULTS

Of 20 patients, contact was possible with 10 patients, but only seven accepted to participate in this study, accounting for 21 restorations [Table/Fig-6]. The sample loss can be explained due to the long-term evaluation; addresses and telephone contacts were modified. Those who were contacted did not respond in the same manner to the motivational stimulus for the recall visit. No follow-up was done between 1 and 14 years.



[Table/Fig-6]: Consort flow diagram.

The distribution of the restorations and the restored teeth are summarised in [Table/Fig-2]. Restorations were equally distributed within posterior teeth as shown by Fisher's-exact test ($p=0.925$). The results of the direct clinical evaluations are detailed in [Table/Fig-7]. Differences were not observed between the evaluated resin composites regarding each of the analysed parameters ($p>0.05$). However, for each resin composite, differences were observed between the observation periods through Friedman's test ($p<0.001$), except for caries incidence. Baseline and 1-year results did not show any differences. Differences were observed when the 14-year data were compared. Colour match, anatomic form and marginal adaptation showed statistically significant results within the observation periods for all three resin composite. For marginal discolouration, only Filtek p60 showed differences within observation periods, at the threshold of significance ($p=0.046$).

After 14 years, failures (Charlie scores) were observed in all three groups for the colour match: 3 Filtek P60 restorations, 2 Surefill and 1 Suprafill. Suprafill also received 1 Delta score for the same parameter. Anatomic form and Marginal adaptation both showed failures for one restoration each of Filtek P60 and Suprafill.

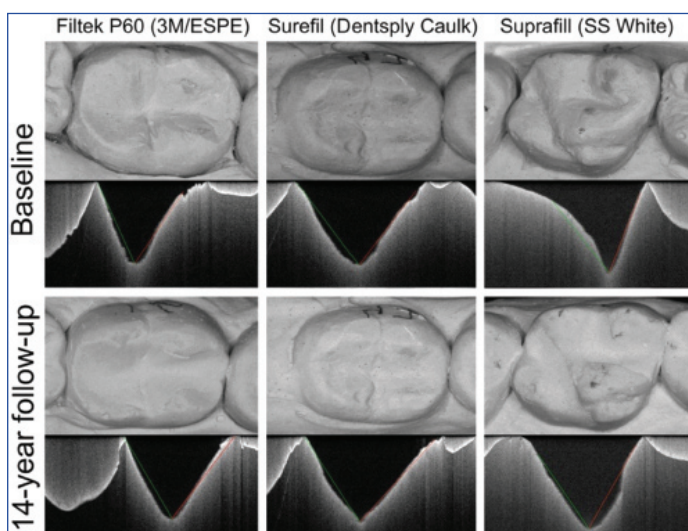
Parameter	Score	BASELINE						1-YEAR						14-YEAR					
		Filtek P60		Surefil		Suprafill		Filtek P60		Surefil		Suprafill		Filtek P60		Surefil		Suprafill	
		n	(%)	n	(%)	n	(%)	n	(%)	n	(%)	n	(%)	n	(%)	n	(%)	n	(%)
Colour match	A	6	(85.7) ^A	5	(71.4) ^A	5	(71.4) ^A	4	(57.1) ^A	5	(71.4) ^A	5	(71.4) ^A	1	(14.3) ^B	3	(42.9) ^B	1	(14.3) ^B
	B	1	(14.3)	2	(28.6)	2	(28.6)	3	(42.9)	2	(28.6)	2	(28.6)	3	(42.9)	2	(28.6)	4	(57.1)
	C	-	-	-	-	-	-	-	-	-	-	-	-	3	(42.9)	2	(28.6)	1	(14.3)
	D	-	-	-	-	-	-	-	-	-	-	-	-	-	-	-	-	1	(14.3)
Cavosurface margin discolouration	A	7	(100) ^A	7	(100)	7	(100)	7	(100)	7	(100)	7	(100)	3	(42.9) ^B	5	(71.4)	5	(71.4)
	B	-	-	-	-	-	-	-	-	-	-	-	-	4	(57.1)	2	(28.6)	2	(28.6)
	C	-	-	-	-	-	-	-	-	-	-	-	-	-	-	-	-	-	-
Caries incidence	A	7	(100)	7	(100)	7	(100)	7	(100)	7	(100)	7	(100)	7	(100)	7	(100)	7	(100)
	C	-	-	-	-	-	-	-	-	-	-	-	-	-	-	-	-	-	-
Anatomic Form	A	7	(100) ^A	7	(100) ^A	7	(100) ^A	7	(100) ^A	7	(100) ^A	6	(85.7) ^A	-	-	-	-	1	(14.3) ^B
	B	-	-	-	-	-	-	-	-	-	-	1	(14.3)	6	(85.7) ^B	7	(100) ^B	5	(71.4)
	C	-	-	-	-	-	-	-	-	-	-	-	-	1	(14.3)	-	-	1	(14.3)
Marginal Adaptation	A	7	(100) ^A	7	(100) ^A	7	(100) ^A	7	(100) ^A	6	(85.7) ^A	6	(85.7) ^A	-	-	1	(14.3) ^B	1	(14.3) ^B
	B	-	-	-	-	-	-	-	-	1	(14.3)	1	(14.3)	6	(85.7) ^B	6	(85.7)	5	(71.4)
	C	-	-	-	-	-	-	-	-	-	-	-	-	1	(14.3)	-	-	1	(14.3)

[Table/Fig-7]: Clinical evaluation through the USPHS method. Different superscript letters indicate significant differences between times of observation through Friedman's test and Wilcoxon signed rank post-hoc test.

The mean wear is shown on [Table/Fig-8]. For each resin composite, Wilcoxon signed rank test did not identify significant differences between buccal and lingual cusps ($p>0.05$). Kruskal Wallis test showed significant differences ($p=0.022$) between the results for the buccal cusps, with the highest values observed for Surefill (303.49 μm) and the lowest for Filtek P60 (43.05 μm). The restoration wear and evaluation images can be observed in [Table/Fig-9].

Reference	Filtek P60	Surefil	Suprafill
Buccal	43.05 (26.20) ^A	303.49 (198.30) ^B	176.42 (121.52) ^{AB}
Lingual	287.75 (110.32)	155.06 (100.08)	152.36 (152.71)
p-value ¹	0.068	0.080	0.225

[Table/Fig-8]: Mean wear (μm) and standard deviation of the restorations through Optical Coherence Tomography (OCT). Different superscript letters indicate significant differences through the Mann-Whitney test.
(1): Through Wilcoxon signed ranks test.



[Table/Fig-9]: Cast replicas photographs and 2D-OCT image evaluation at baseline and 14-years of follow-up for the evaluated resin composites.

DISCUSSION

Restorative materials are continuously formulated and marketed. Therefore, long-term clinical studies evaluating their efficacy and durability should be encouraged [1,11]. Randomised clinical trials are strong scientific evidence [4]. This study aimed to evaluate the clinical performance of three resin composites indicated for posterior teeth restorations and their wear after 14 years.

After 14 years, an overall success rate of 89.52% was observed. Overall success rates are calculated based on the number of acceptable restorations (Alpha or Bravo ratings) during the whole evaluation period (94 acceptable restorations in a total of 105). In the one-year evaluation, the overall success rate of 100% (105/105) was observed. The annual failure rate, however, informs the percentage of possible failures (Charlie or Delta ratings) per year in this study was 0.74% (11 failed restorations out of 105, divided by 14 years). High clinical success rates (over 90%) were observed even after an extended evaluation time (more than 8 years) [28,29]. An 18-year clinical follow-up of composite resin occlusal restorations also observed promising results with low annual failure rates (2.1%) [6].

Colour match was inadequate in 33.3% after 14 years [Table/Fig-7]. In one-year, no restoration received unsatisfactory evaluations (14 alpha and 7 bravo) for the same parameter, indicating that time is a determinant factor for colour match success. Resin composite restorations are very susceptible to pigmentation when exposed to exogenous dyes [30]. The pigmentation is related to the degree of water sorption and the hydrophilic or hydrophobic characteristics of the resin matrix [30,31]. There is compatibility of the polymer phase of the resin composites with yellow dyes, which can adsorb and penetrate the organic matrix of the resin composites [31,32]. Also, inorganic filler detachment from the surface of the resin composites causes irregularities that favors the penetration of the pigments [32]. Foods with low pH may cause further damage to the materials' surface, increasing the susceptibility to staining [33]. Furthermore, the translucency decreases over the years [22,34].

The discolouration of the cavosurface margin was satisfactory in all restorations at 1 and 14-year evaluation. Piva F et al., evaluated three resin composites in 34 primary molars for six months using USPHS criteria [35]. Filtek™ P60 presented less satisfactory results concerning margin discolouration when compared to two micro hybrid resins composite (Charisma and Filtek Z250) [35]. The authors attributed these results to possible differences within the inorganic phase of the material, type, concentration and size could have accounted for greater difficulty in polishing [36,37].

Secondary caries was also not observed throughout the observation period, which is in agreement with previous studies with two and three years of follow-up [24,25,38]. The execution of restorations with a rubber dam, previous prophylaxis and

incremental technique has been reported to reduce the caries incidence and problems related to handling in clinical evaluation of 36 months [39]. A systematic review and meta-analysis by Heintze SD et al., observed that caries adjacent to the restoration was infrequent and that restorations that were placed with a rubber dam showed fewer caries at the margins than restorations that were placed without a rubber dam [40].

Anatomicform and marginal adaptation parameters had two failures at 14-years, one Filtek P60 and one Suprafil restoration for each parameter. The one-year evaluation showed that all restorations were acceptable. The Surefil/Dentsply Caulk resin composite was the only one that received satisfactory evaluations after 14 years for these parameters. In eight-year clinical evaluation, only one composite resin restoration of 213 was classified as a failure for the anatomic form parameter [28]. While in another study an extended evaluation time, for the same parameter, 81% and 65% of resin composite restoration received an alpha score, for five and eight-year evaluation, respectively [29].

Restorative materials wear is influenced by the composition of the resin composite [41]. Materials with higher inorganic filler concentration tend to exhibit higher mechanical resistance and lower wear values [7]. Fillers size, shape and hardness, as well as the organic matrix ratio, can influence the wear resistance [7,42,43]. In this study, differences were only observed between materials within the buccal cusp. However, buccal triturating slopes were equally distributed among groups, in a sense that the restored tooth could not help to explain these results.

Optical coherence tomography is an efficient tool for the quantitative evaluation of restorative materials wear through replicate models. In addition, it is considered a non-destructive, non-invasive, with high resolution, fast and easy image acquisition [15,17,20]. In clinical settings, with direct observation of the restorations, OCT has also been able to detect the presence of air bubbles, cracking points, fractures, resin step shifts, gaps and possible agglomerates of inorganic particles [42].

LIMITATION

Loss of contact with patients was a limiting factor in the present study. However, considering the split-mouth study design, the losses occurred equally for all three study groups. Intra oral Optical Coherence Tomography evaluations could favor clinical evaluations in future studies.

CONCLUSION

The condensable/packable resin composites (Filtek™ P60/3M-ESPE and Surefil/Dentsply Caulk) and microhybrid (Suprafil/SS White) presented a satisfactory performance after 14 years. These materials can be safely indicated for clinical use in posterior restorations. The cast replica analysis by OCT showed accurate and precise evaluations and is a viable method of follow-up evaluations. The OCT findings were consistent with the clinical observations.

REFERENCES

- [1] Ilie N, Hilton TJ, Heintze SD, Hickel R, Watts DC, Silikas N, et al. Academy of dental materials guidance-resin composites: part I-mechanical properties. *Dent Mat.* 2017;33(8):880-94.
- [2] Casagrande L, Seminario AT, Correa MB, Werle SB, Maltz M, Demarco FF, et al. Longevity and associated risk factors in adhesive restorations of young permanent teeth after complete and selective caries removal: a retrospective study. *Clin oral investig.* 2017;21(3):847-55.
- [3] Moraschini V, Ka Fai C, Alto RM, Santos GO. Amalgam and resin composite longevity of posterior restorations: A systematic review and meta-analysis. *J Dent.* 2015;43(9):1043-50.
- [4] De Albuquerque Lima CF, De Souza FB, Da Silva CHV. Resinas compostas em dentes posteriores: uma revisão sistemática. *Arq Odontol.* 2016;42(3):211-20.
- [5] Ástvaldsdóttir A, Dagerhamn J, Dijken JDV, Naimi-Akbar A, Sandborgh-Englund G, Tranaeus S, et al. Longevity of posterior resin composite restorations in adults—a systematic review. *J Dent.* 2015;43(8):934-54.
- [6] Van de Sande FH, Rodolpho PAR, Basso GR, Patias R, Rosa QF, Demarco FF, et al. 18-year survival of posterior composite resin restorations with and without glass ionomer cement as base. *Dent Mat.* 2015;31(6):669-75.
- [7] Heintze S, Ilie N, Hickel R, Reis A, Loguercio A, Rousson V. Laboratory mechanical parameters of composite resins and their relation to fractures and wear in clinical trials-A systematic review. *Dent Mat.* 2017;33(3):101-14.
- [8] Deliperi S, Bardwell DN. An alternative method to reduce polymerization shrinkage in direct posterior composite restorations. *JADA.* 2002;133(10):1387-98.
- [9] Mesko ME, Onofre RS, Niek MSC, Bas JO, Cenci LTP. Rehabilitation of severely worn teeth: A systematic review. *J Dent.* 2016;48(1):9-15.
- [10] Santos MJMC. A Restorative Approach for Class II Resin Composite Restorations: A Two-Year Follow-up. *Oper Dent.* 2015;40(1):19-24.
- [11] Singh P, Kumar N, Singh R, Kiran K, Kumar S. Overview and recent advances in composite resin: A review. *Int J Sci Stud.* 2015;3(9):169-172.
- [12] Rodrigues-Junior SA, Chemin P, Piaia PP, Ferracane JL. Surface roughness and gloss of actual composites as polished with different polishing systems. *Oper Dent.* 2015;40(1):1-12.
- [13] Van Dijken JW, Pallesen U. Randomized 3-year clinical evaluation of Class I and II posterior resin restorations placed with a bulk-fill resin composite and a one-step self-etching adhesive. *J Adhes Dent.* 2015;17(1):81-88.
- [14] Veiga AMA, Cunha AC, Ferreira DMTP, Fidalgo TKS, Chianca TK, Reis KR, et al. Longevity of direct and indirect resin composite restorations in permanent posterior teeth: a systematic review and meta-analysis. *J Dent.* 2016;54(1):1-12.
- [15] Schneider H, Park KJ, Rueger C, Ziebolz D, Krause F, Haak R. Imaging resin infiltration into non-cavitated carious lesions by optical coherence tomography. *J Dent.* 2017;60(1):94-98.
- [16] Shimada Y, Sadr A, Sumi Y, Tagami J. Application of optical coherence tomography (octl) for diagnosis of caries, cracks, and defects of restorations. *Curr Oral Health Rep.* 2015;2(1):73-80.
- [17] Fernandes LO, Mota CCBO, Melo LSA, Soares MUSC, Feitosa DS, Gomes ASL. In vivo assessment of periodontal structures and measurement of gingival sulcus with optical coherence tomography: a pilot study. *J Biophotonics.* 2017;10(1):6-7.
- [18] De Moraes MCD, Freitas AZ, Aranha ACC. Progression of erosive lesions after Nd: YAG laser and fluoride using optical coherence tomography. *Lasers med Sci.* 2017;32(1):1-8.
- [19] Schneider H, Park KJ, Häfer M, Rüger C, Schmalz G, Krause F, et al. Dental applications of Optical Coherence Tomography (OCT) in cariology. *Appl Sci.* 2017;7(5):472-80.
- [20] Monteiro GQM, Montes AMJR, Gomes ASL, Mota CCBO, Campelo SL, Freitas AZ. Marginal analysis of resin composite restorative systems using optical coherence tomography. *Dent Mat.* 2011;27(1):e213-23.
- [21] Monteiro GQM, Montes MAJR, Rolim TB, Mota CCBO, Kyotoku BBC, Gomes ASL, et al. Alternative methods for determining shrinkage in restorative resin composites. *Dent Mat.* 2011;27(8):e176-85.
- [22] ALShetili MSM, Al-Omari M. Colour stability of nano-filled, micro-hybrid, and silorane-based dental composite resin materials. *S J Oral Sci.* 2016;3(1):42-48.
- [23] Kocağaoglu H, Aslan T, Gürbulak A, Albayrak H, Taşdemir Z, Gumus H. Efficacy of polishing kits on the surface roughness and colour stability of different composite resins. *Niger J Clin Pract.* 2017;20(5):557-565.
- [24] Walter R, Boushell L, Heymann HO, Ritter A, Sturdevant JR, Wilder Jr AD, et al. Three-year clinical evaluation of a silorane composite resin. *J Esthet Restor Dent.* 2014;26(3):179-90.
- [25] Gianordoli-Neto R, Padovani GC, Mondelli J, Navarro NFL, Mendonça JS, Santiago SL. Two-year clinical evaluation of resin composite in posterior teeth: A randomized controlled study. *JCDR.* 2016;19(4):306-10.
- [26] Baracco B, Fuentes MV, Ceballos L. Five-year clinical performance of a silorane- vs a methacrylate-based composite combined with two different adhesive approaches. *Clin. oral investig.* 2016;20(5):991-1001.
- [27] De Souza FB, Guimarães RP, Silva CHV. A clinical evaluation of packable and microhybrid resin composite restorations: one-year report. *Quintessence int.* 2005;36(1):41-48.
- [28] Collins CJ, Bryant RW, Hodge KLV. A clinical evaluation of posterior composite resin restorations: 8-year findings. *J Dent.* 1998;26(4):311-17.
- [29] Barnes DM, Blank LW, Thompson VP, Holston AM, Gingell JC. A 5- and 8-year clinical evaluation of a posterior composite resin. *Quintessence Int.* 1991;22(2):143-51.
- [30] Habib ANEA, Abdelmoniem AS, Mahmoud AS. Effect of children's drinks on colour stability of different dental composites: An in vitro study. *J Clin Ped.* 2017;41(2):120-25.
- [31] Ardu S, Duc O, Di Bella E, Krejci I. Colour stability of recent composite resins. *Odontology.* 2017;105(1):29-35.
- [32] Nair SR, Niranjana NT, Jayasheel A, Suryakanth DB. Comparative evaluation of colour stability and surface hardness of methacrylate based flowable and packable composite-in vitro study. *JCDR.* 2017;11(3):ZC51-ZC54.
- [33] Dias HB, Carrera ET, De Souza RAN. The influence of pH and chemical composition of beverages on colour stability of a nanofilled composite resin. *Gen Dent.* 2016;64(6):e21-e27.
- [34] Hoseinifard R, Mortazavi-Lahijani E, Mollahassani H, Ghaderi A. One year clinical evaluation of a low shrinkage composite compared with a packable composite resin: A randomized clinical trial. *JDT.* 2017;14(2):84-91.
- [35] Piva F, Ribeiro CS, Coelho-de-Souza FH. Avaliação clínica de restaurações de resina composta em molares decíduos-estudo piloto. *APCD.* 2014;68(1):69-74.

- [36] Salgado VE, Albuquerque PAC, Cavalcante LM, Pfeifer CS, Moraes RR, Schneider LFJ. Influence of photoinitiator system and nanofiller size on the optical properties and cure efficiency of model composites. *Dent Mat.* 2014;30(10):e264-71.
- [37] Salgado VE, Cavalcante LM, Moraes RR, Davis HB, Ferracane JL, Schneider LFJ. Degradation of optical and surface properties of resin-based composites with distinct nanoparticle sizes but equivalent surface area. *J Dent.* 2017;59(1):48-53.
- [38] Novaes JR, Batista J, Pimenta FD, Cortés ME. Evaluación clínica de restauraciones clase I de resina compuesta condensable después de 2 años. *A Odontol Venezolana.* 2007;45(1):61-66.
- [39] Gerhardt-Szep S, Schröder-Schichtel E, Quanita Z, Zahn T, Feierabend S, Rüttermann S. Problems of Direct Composite Posterior Restorations: A Clinical Study. *J Dent Prob.* 2016;3(1):35-39.
- [40] Heintze SD, Rousson V, Hicke R. Clinical effectiveness of direct anterior restorations—A meta-analysis. *Dent Mat.* 2015;31(5):481-95.
- [41] Gonçalves L, Amaral CM, Poskus LT, Guimarães JGA, Silva EM. Degradation of resin composites in a simulated deep cavity. *Brazilian Dental Journal.* 2014;25(6):532-37.
- [42] Mota CBO, Guerra BA, Machado BSA, Cabral AJ, Gomes ALS. Optical coherence tomography applied to the evaluation of wear of composite resin for posterior teeth. *Biophotonics South America.* 2015;1(1):1-8.
- [43] Fleigel JD, Sutton AJ. Reliable and repeatable centric relation adjustment of the maxillary occlusal device. *J Prosthodont.* 2013;22(3):233-36.

PARTICULARS OF CONTRIBUTORS:

1. Masters, Department of Dentistry, University of Pernambuco—UPE, Camaragibe, Pernambuco, Brazil.
2. Ph.D, Department of Dentistry, Federal University of Pernambuco, Recife, Pernambuco, Brazil.
3. Ph.D, Department of Dentistry, Federal University of Pernambuco, Recife, Pernambuco, Brazil.
4. Ph.D, Department of Dentistry, University of Pernambuco—UPE, Cabaragibe, Pernambuco, Brazil.
5. Ph.D, Department of Dentistry, Federal University of Pernambuco, Recife, Pernambuco, Brazil.
6. Masters, Department of Dentistry, Federal University of Pernambuco, Recife, Pernambuco, Brazil.
7. Ph.D, Department of Dentistry, Federal University of Pernambuco, Recife, Pernambuco, Brazil.

NAME, ADDRESS, E-MAIL ID OF THE CORRESPONDING AUTHOR:

Luís Felipe Espíndola-Castro,
Av. General Newton Cavalcanti, 1650-Tabatinga, Zip Code: 54.756-220, Camaragibe, Pernambuco, Brazil.
E-mail: drfelipeespindola@gmail.com

FINANCIAL OR OTHER COMPETING INTERESTS: None.

Date of Submission: **Jun 05, 2018**

Date of Peer Review: **Jul 10, 2018**

Date of Acceptance: **Oct 26, 2018**

Date of Publishing: **Jan 01, 2019**